



PRESENTING CLINICAL SIGNS

History: New grade II/VI murmur. Crackles. Concern for pulmonary hypertension.

DATE

12/30/22

ECHOCARDIOGRAPHIC FINDINGS

2D, M-mode, and Doppler study.

PERFORMED BY:

Shari Reffi, CVT

INTERPRETED BY

Keith Blass, DVM,
MS, DACVIM
(Cardiology)

Left atrial size is normal. The mitral valve leaflets are mildly thickened and exhibit mild systolic prolapse. A mild jet of eccentric mitral regurgitation is present. Left ventricular dimensions are normal. Left ventricular systolic function is mildly hyperdynamic. The aorta and aortic valve are normal. Right atrial and right ventricular dimensions are normal. The tricuspid valve leaflets are mildly thickened, and a mild jet of tricuspid regurgitation is present. TR velocity does not suggest the presence of pulmonary hypertension. The pulmonary artery and pulmonic valve are normal. No heartworms are visualized. No pericardial effusion or cardiac masses are seen.

PATIENT

Trixie Sabella

LA - 21.0 mm
LVIDd - 20.4 mm
LVIDs - 11.6 mm
FS - 43%
RA - 15.0 mm
LVOT - 1.16 m/s
RVOT - 0.95 m/s
TR - 2.01 m/s

SPECIES

Canine

BREED

Mixed

ASSESSMENT/RECOMMENDATIONS

Degenerative mitral and tricuspid valve disease

This examination demonstrates mild regurgitation of blood across Trixie's mitral and tricuspid valves resulting from degenerative valve disease. The hemodynamic effects of each of the regurgitations also appear to be mild, as Trixie does not have secondary dilation of any of her cardiac chambers. As such, Trixie's valvular diseases appear to be well-compensated, and her pulmonary crackles do not appear to be cardiogenic in origin.

No evidence of pulmonary hypertension is seen in this exam.

SEX

Thoracic radiographs are recommended to further evaluate Trixie's pulmonary crackles.

FS

No therapy is recommended at this stage of Trixie's valvular diseases.

AGE

13 y

A recheck echocardiogram is recommended in 6 months to monitor for disease progression.

WEIGHT

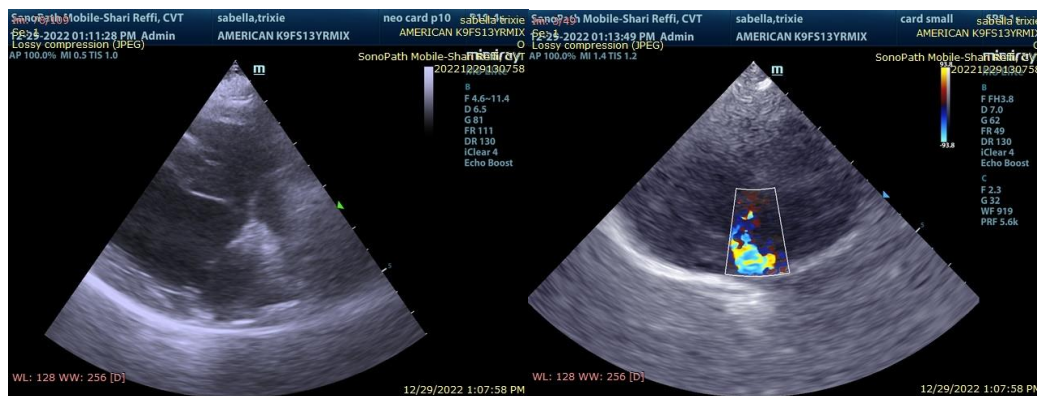
8.5 lb

HOSPITAL NAME

American AH

REFERRING VET

Dr. Stockmal





DATE The information and recommendations provided are based on the images presented by the referring veterinarian. No evaluation can be communicated regarding pathology that was not visible in the image/video clips provided.

12/30/22

Thank you for this referral. If the clinical or image interpretation does not parallel your findings or if I can be of any further assistance please contact me.

PERFORMED BY:

Shari Reffi, CVT

Keith Blass, DVM, MS, DACVIM (Cardiology)
KeithBlass@gmail.com
631-804-5754

INTERPRETED BY

Keith Blass, DVM,
MS, DACVIM
(Cardiology)

PATIENT

Trixie Sabella

SPECIES

Canine

BREED

Mixed

SEX

FS

AGE

13 y

WEIGHT

8.5 lb

HOSPITAL NAME

American AH

REFERRING VET

Dr. Stockmal